

ALL ABOUT CHOROIDAL NEVI

Amy C. Scheffler, MD, Ocular Oncology Specialist

What is a choroidal nevus?

A choroidal nevus is a collection of pigmented or nonpigmented cells in the choroid, the vascular layer of the eye. Nevus is essentially a medical word for freckle or mole. Nevi refers to multiple lesions.

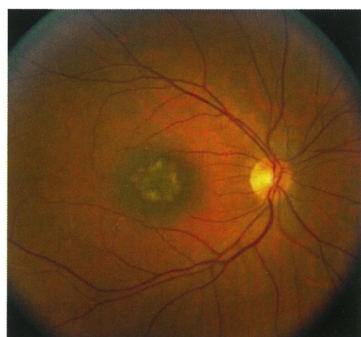
Are choroidal nevi common?

Yes, these are very common, especially in Caucasian patients, maybe as common as 1 in every 10 people.

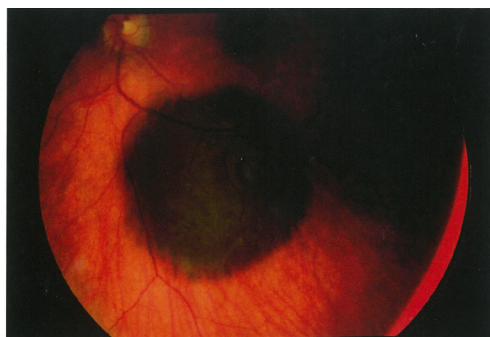What is the treatment for a choroidal nevus?

Generally, choroidal nevi are just observed in order to assess whether they are growing (and therefore acting biologically more like a choroidal melanoma, a cancer).

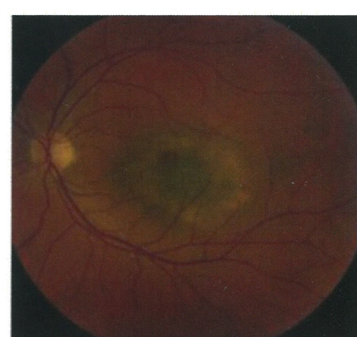
Dr. Scheffler will examine your eye periodically in the office and will perform detailed imaging studies such as ultrasound, photographs, optical coherence tomography, and fluorescein angiography to assess whether the nevus is growing or changing.



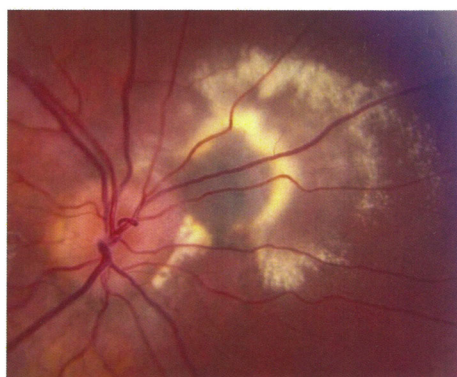Choroidal nevus in the macula, the center part of the retina responsible for reading.



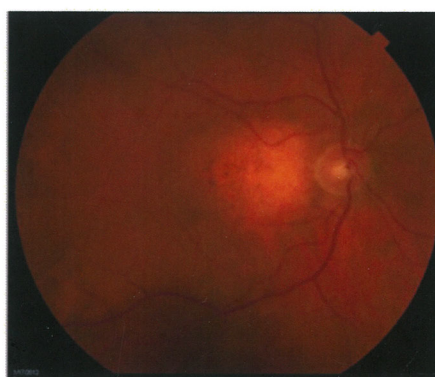Round, flat choroidal nevus



Round, flat choroidal nevus



Choroidal nevus near the optic nerve with a choroidal neovascular membrane leaking fluid and cholesterol exudates.



Amelanotic (without pigment) nevus in the macula, the center part of the retina responsible for reading.

Are nevi/melanomas inherited?

In less than 5% of patients, nevi/melanoma can be associated with a genetic abnormality, which can be detected by doing blood work. Patients with this genetic abnormality are more likely to have a freckle/nevus that becomes a true cancer and are also at risk of developing other (non-ocular) cancers.

How often do choroidal nevi grow into a melanoma?

Overall, only a small percentage do grow. Over the years, we have learned to identify which clinical features are found more commonly in nevi that do grow into melanomas.

Features which make nevi more high-risk include:

- Thickness > 2 mm
- Orange pigment
- Certain features on ultrasound
- Location next to the optic nerve
- Visual symptoms
- Lack of features signaling chronicity
- Fluid under the retina

Depending on how many of these features your nevus has, Dr. Scheffler will decide how frequently you need to be seen again.

Do I need a biopsy?

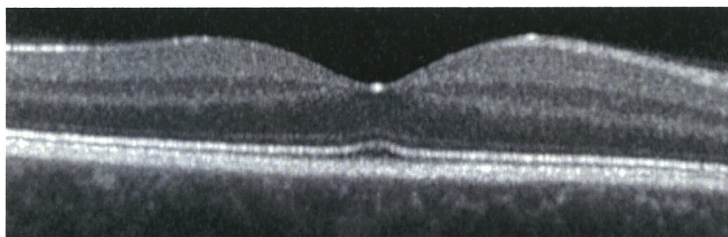
Biopsies are rarely performed for small nevi in ocular oncology. Most nevi just require periodic observation in clinic.

Do I have cancer?

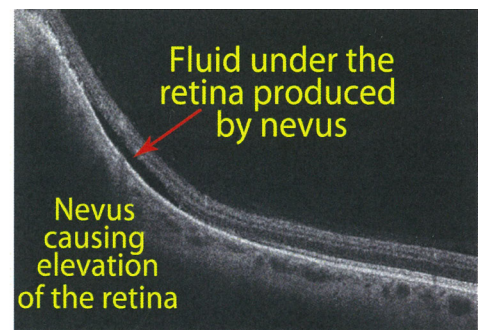
A nevus is a pre-cancerous condition, similar to a freckle on your skin. Just as a majority of freckles on the skin don't grow into cancer, it is also rare for a nevus to grow into cancer.

What happens if my nevus grows?

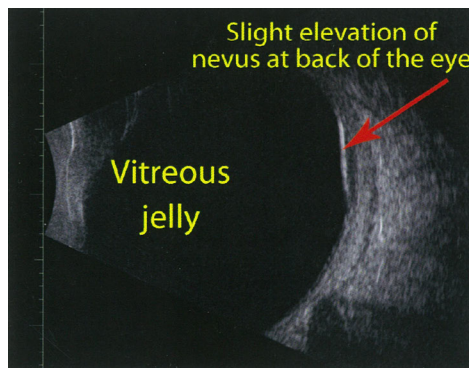
Nevi rarely grow quickly and transform into a melanoma, which is a true cancer of the eye. We treat these cancers with surgery and/or radiation.



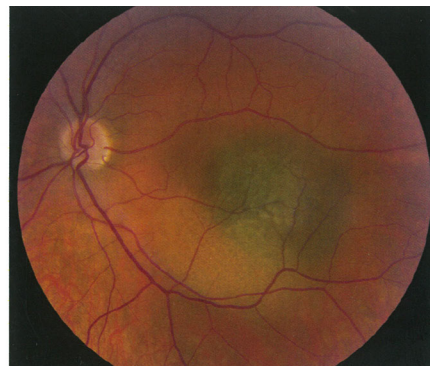Normal macula OCT



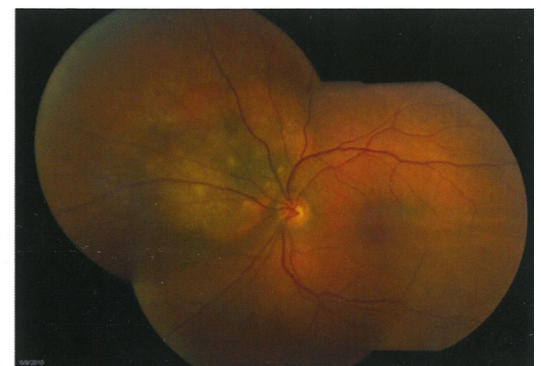
OCT of nevus



Ultrasound of a small nevus



Macular nevus



Nevus with orange pigment and fluid (risk factors for growth)